



Evaluation of The Effectiveness of Rotational Conjunctival Flap Compared to Bare Sclera with Mitomycin C After Surgical Removal of Primary Pterygium

Akhtar Amin¹, Ambreen Ahmad¹, Arshad Iqbal¹, Sher Akbar Khan¹

¹Saidu Teaching Hospital, Swat, KP, Pakistan.

ARTICLE INFO

Keywords: Primary Pterygium, Rotational Conjunctival Flap, Mitomycin C, Recurrence.

Correspondence to: Akhtar Amin, Saidu Teaching Hospital, Swat, KP, Pakistan. Email: akhtaraminccs@gmail.com

Declaration

Authors' Contribution: All authors equally contributed to the study and approved the final manuscript.*Detail is given at the end.

Conflict of Interest: No conflict of interest.

Funding: No funding received by the authors.

Article History

Received: 08-02-2025, Revised: 04-04-2025
Accepted: 24-04-2025, Published: 11-05-2025

ABSTRACT

Background: Primary pterygium is a common ocular condition requiring effective surgical management to minimize recurrence. While mitomycin C is frequently used as an adjunct in pterygium surgery, rotational conjunctival flap offers an anatomical restoration approach. Their comparative efficacy remains a subject of investigation. **Objective:** To compare the efficacy of rotational conjunctival flap and mitomycin C after surgical removal of primary pterygium. **Study Design:** Randomized controlled trial. **Duration and Place of Study:** This study was conducted from February 2024 to January 2025 at the Department of Ophthalmology, Saidu Group of Teaching Hospital, Swat. **Methodology:** A total of 196 patients with primary pterygium, aged 18–60 years, were randomized into two equal groups. Group A underwent rotational conjunctival flap surgery, while Group B received 0.04% MMC application during surgery. Exclusion criteria included systemic diseases, recurrent pterygium, and corneal pathologies. Surgical outcomes were assessed over six months, with efficacy defined as the absence of fibrovascular regrowth ≥ 1 mm beyond the limbus. **Results:** Group A demonstrated significantly higher efficacy (90.8%) compared to Group B (76.5%, $p=0.007$). Stratified analysis revealed superior outcomes for rotational conjunctival flap across various subgroups, including patients >45 years, males, right-eye involvement, and pterygium duration >18 months. Both techniques were well tolerated, with no major complications reported. **Conclusion:** Rotational conjunctival flap surgery is significantly more effective than mitomycin C in preventing recurrence of primary pterygium.

INTRODUCTION

Primary pterygium is a fibrovascular growth of the conjunctiva onto the cornea, usually arising nasally.¹ It is most classically associated with chronic exposure to UV light, wind, and dust, making it more common in people living in sunny and dry climates.² Symptoms range from mild irritation and redness to significant visual impairment due to astigmatism or encroachment on the visual axis.³ Although the exact pathogenesis is unknown, it probably involves UV-induced damage, followed by the action of oxidative stress and a proliferative response of the conjunctiva.⁴ Non-treated primary pterygium can cause cosmetic disturbances, discomfort, or functional disturbances.⁵

The management of primary pterygium may be either medical or surgical. Medical treatment is symptomatic and includes lubricants, anti-inflammatory agents, and UV protection.⁶ Indications towards surgical excision include progressive pterygium and impairment of vision and for cosmetic reasons.⁷ A number of surgical methods are being developed to lessen the recurrence-a

frequent postoperative dilemma. These range from bare sclera excision and conjunctival auto grafting to amniotic membrane transplantation, and finally to adjunctive therapies such as mitomycin C or β -radiation.⁸ Each of these methods has its disadvantages and advantages, with recurrence rates and complication risks being the key determinants of their effectiveness.⁸

However, the rotational conjunctival flap technique has been one of the effective surgical methods for managing pterygium.⁹ In this technique, part of the conjunctiva is rotated adjacent to the site of excision to cover the bare sclera left after the removal of the pterygium. This surgery hastens the process of healing and reduces the recurrence rate by acting as a physical barrier to the growth of fibrovascular tissue.⁹ This is different from the classic bare sclera excision, as the rotational flap incorporates with the surrounding tissue, thus often giving a better cosmetic result with reduced recurrence rates.¹⁰ This method is particularly useful for

patients in whom conjunctiva auto graft may not be considered due to scarcity of the donor tissue.

Mitomycin C (MMC) is also known as adjunctive therapy applied for reducing the rate of recurrence following pterygium surgery.¹¹ Commonly in bare sclera techniques, the role of Mitomycin C in an extremely high dosage of powerful antimetabolite involves merely preventing the replication and proliferation of fibroblast.¹² Consequently, there would be hindrances in regrowth and overgrowing pterygium. MMC normally could be administered intraoperative and even post operation. It generally adopts a local application method, besides some others researched which report that it would considerably lower recurrence rates.¹³ However, its application is related to the possibility of complications including scleral thinning, delayed healing, and secondary infections.¹⁴ Even with these complications, MMC is an important alternative for high-risk patients or when other methods of surgery are not practical, as long as dosing and follow-up care are done properly.

Research conducted by Gupta VP and colleagues demonstrated that the success rate of rotational conjunctival flap technique was 96.67%, while mitomycin C achieved a 100% success rate following primary pterygium excision.¹⁵ In a separate investigation by Narsani AK and team, the effectiveness of rotational conjunctival flap was reported at 94.3%, compared to an 81% success rate with mitomycin C after primary pterygium surgery.¹⁶

This study is essential to evaluate and compare the efficacy of rotational conjunctival flap and mitomycin C in the management of primary pterygium. Despite existing research, conflicting success rates and potential variations in outcomes across different populations highlight the need for further investigation.^{15,16} Understanding these differences will help optimize treatment protocols and ensure better patient outcomes.

METHODOLOGY

This randomized controlled trial was carried out from February 2024 to January 2025 at the Department of Ophthalmology, Saidu Group of Teaching Hospital, Swat. A total of 196 patients with primary pterygium were included in the study, with 98 patients in each group (rotational conjunctival flap and mitomycin C). The sample size was determined with 80% power and a 95% confidence level, considering an anticipated efficacy of 94.3% for rotational conjunctival flap compared to 81% for mitomycin C.¹⁶ Eligible participants were aged 18 to 60 years, of both genders, and had primary pterygium defined as fibrovascular tissue extending 2 mm or more from the limbus onto the cornea on corneal topography. Patients with a history of collagen vascular or autoimmune diseases, pregnancy, ocular surface pathology or infection, previous limbal

surgery, recurrent or pseudo-ptyerygium, lime injury with symblepharon, ocular injuries, or corneal opacities and degeneration were excluded. After ethical approval and informed consent, demographic data were recorded. Blocked randomization was used to allocate participants into Group A (rotational conjunctival flap) or Group B (mitomycin C). All surgeries were performed by a single consultant surgeon. For Group A, fibrovascular tissue was excised and rotated 180° to place its nasal side near the limbus, sutured with 10-0 nylon. For Group B, 0.04% mitomycin C was applied to the scleral bed for 2 minutes, followed by irrigation with 50 mL normal saline. Postoperatively, topical corticosteroid-antibiotic combination ointment was applied, and the eye was patched for 24 hours. Follow-up visits were scheduled on postoperative days and then every two months. Recurrence, defined as postoperative fibrovascular regrowth of 1 mm or more crossing the corneoscleral limbus on corneal topography, was assessed at 6 months. Data were analyzed using IBM SPSS version 23. Frequencies and percentages were calculated for qualitative variables, while mean \pm SD was computed for quantitative variables. The chi-square test was applied to compare efficacy, defined as the absence of recurrence, between the two groups. A p-value \leq 0.05 was considered statistically significant.

RESULTS

The study compared the efficacy of rotational conjunctival flap (Group A) and mitomycin C (Group B) following the surgical removal of primary pterygium, involving 196 patients equally distributed between the groups. The mean age in Group A was 50.53 ± 10.08 years, slightly higher than Group B at 47.81 ± 8.99 years. The mean duration of primary pterygium was longer in Group A (18.32 ± 10.44 months) compared to Group B (13.32 ± 6.92 months). Most patients were male, with 78.6% in Group A and 75.5% in Group B. Right-eye involvement was observed in 48% of Group A and 51% of Group B, while left-eye involvement accounted for 52% in Group A and 49% in Group B. Hypertension was present in 32.7% of Group A and 33.7% of Group B, and diabetes was more prevalent in Group B (28.6%) than in Group A (15.3%) as shown in Table-I.

Table I

Demographics of the patients (n=196)

Demographics	Group A n=98	Group B n=98
	Mean \pm SD	Mean \pm SD
Age (years)	50.530 \pm 10.08	47.806 \pm 8.99
Duration of primary pterygium (months)	18.316 \pm 10.44	13.316 \pm 6.92
Gender	Male n(%)	74 (75.5%)
	Female n(%)	24 (24.5%)
Side of Eye	Right n(%)	50 (51%)
	Left n(%)	48 (49%)
Hypertension	Yes n(%)	33 (33.7%)

	No n(%)	66 (67.3%)	65 (66.3%)
Diabetes	Yes n(%)	15 (15.3%)	28 (28.6%)
	No n(%)	83 (84.7%)	70 (71.4%)

Group A demonstrated significantly higher efficacy (90.8%) compared to Group B (76.5%) with a p-value of 0.007 as shown in Table-II.

Table II

Comparison of efficacy between the two groups (n=196)

Efficacy	Group A n=98 n (%)	Group B n=98 n (%)	P value
Yes	89 (90.8%)	75 (76.5%)	0.007
No	9 (9.2%)	23 (23.5%)	
Total	98 (100%)	98 (100%)	

Stratified analysis revealed superior outcomes for Group A across most subgroups. Among patients >45 years, Group A showed 94% efficacy compared to 73.2% in Group B (p=0.002). Male patients had 92.2% efficacy in Group A versus 75.7% in Group B (p=0.006), and female patients showed 85.7% efficacy in Group A versus 79.2% in Group B. Right-eye involvement resulted in higher efficacy in Group A (93.6%) compared to Group B (80%, p=0.049), while left-eye involvement was similar but not statistically significant. For patients with pterygium duration >18 months, Group A had 95.9% efficacy compared to 76.9% in Group B (p=0.011). Hypertensive patients in Group A exhibited 93.8% efficacy versus 84.8% in Group B, and non-hypertensive patients had 89.4% efficacy in Group A versus 72.3% in Group B (p=0.013). Among non-diabetic patients, Group A showed significantly better efficacy (92.8%) compared to Group B (78.6%, p=0.011), while diabetic patients had similar outcomes in both groups as shown in Table-III.

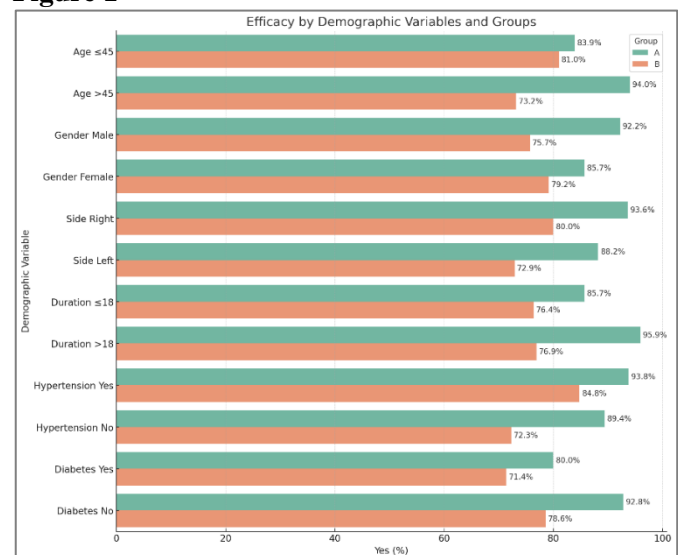
Table III

Stratification of Efficacy Based on Demographic Variables Across Groups

Demographics variables	Group	Efficacy		P-value	
		Yes (n, %)	No (n, %)		
Age (years)	≤ 45	A	26 (83.9%)	5 (16.1%)	0.747
		B	34 (81%)	8 (19%)	
	>45	A	63 (94%)	4 (6%)	
		B	41 (73.2%)	15 (26.8%)	
Gender	Male	A	71 (92.2%)	6 (7.8%)	0.006
		B	56 (75.7%)	18 (24.3%)	
	Female	A	18 (85.7%)	3 (14.3%)	
		B	19 (79.2%)	5 (20.8%)	

Side of Eye	Right	A	44 (93.6%)	3 (6.4%)	0.049
		B	40 (80%)	10 (20%)	
	Left	A	45 (88.2%)	6 (11.8%)	
		B	35 (72.9%)	13 (27.1%)	
Duration of primary pterygium (months)	≤18	A	42 (85.7%)	7 (14.3%)	0.207
		B	55 (76.4%)	17 (23.1%)	
	>18	A	47 (95.9%)	2 (4.1%)	
		B	20 (76.9%)	6 (23.1%)	
Hypertension	Yes	A	30 (93.8%)	2 (6.2%)	0.247
		B	28 (84.8%)	5 (15.2%)	
	No	A	59 (89.4%)	7 (10.6%)	
		B	47 (72.3%)	18 (27.7%)	
Diabetes	Yes	A	12 (80%)	3 (20%)	0.539
		B	20 (71.4%)	8 (28.6%)	
	No	A	77 (92.8%)	6 (7.2%)	
		B	55 (78.6%)	15 (21.4%)	

Figure 1



DISCUSSION

The results demonstrated significantly higher efficacy with the use of rotational conjunctival flap compared to mitomycin C across most demographic and clinical subgroups. The superior outcomes observed with rotational conjunctival flap can be explained by its ability to provide a physical barrier that prevents fibrovascular regrowth, a common cause of recurrence in pterygium surgery. On the other hand, the efficacy of mitomycin C, though substantial, may have been limited due to variability in application technique and individual

patient response, highlighting the significance of anatomical restoration over pharmacological intervention for better postoperative outcomes. The study findings align with previous research in several aspects while also highlighting some differences. Our study demonstrated that rotational conjunctival flap surgery (efficacy 90.8%) was significantly more effective than mitomycin C (MMC) application (efficacy 76.5%) in preventing pterygium recurrence ($p=0.007$). These findings corroborate those of Ozsutcu et al.¹⁷ where rotational conjunctival flap alone had higher recurrence rates (26.6%) compared to rotational flap with MMC (13.3%), and rotational flap with bevacizumab (10%) further reduced recurrence. Similarly, Gupta et al.¹⁸ reported no recurrence in patients treated with MMC (0.04%) over six months compared to a 20% recurrence rate in patients without MMC. These studies, including ours, consistently show that adjunctive treatments with MMC or similar agents enhance outcomes compared to standalone techniques.

Koranyi et al.¹⁹ reported that conjunctival autograft had a significantly lower recurrence rate (15%) compared to MMC (38%) after four years, which differs from our results where MMC showed a relatively lower recurrence rate. This discrepancy could be attributed to differences in follow-up duration, as recurrence rates tend to increase over time, especially for MMC-treated cases, as noted by Koranyi et al. ($p<0.05$). Moreover, Alpay et al.²⁰ highlighted that conjunctival autografting resulted in the lowest recurrence rate (16.6%) among four techniques, emphasizing its efficacy in reducing recurrence. Our study similarly supports the effectiveness of anatomical restoration methods like rotational conjunctival flap over chemical adjuncts.

Interestingly, demographic factors also influenced outcomes. Our study found that older patients (>45 years) and non-diabetic patients in the rotational conjunctival flap group experienced significantly better outcomes than their counterparts in the MMC group ($p=0.002$ and $p=0.011$, respectively). These results are consistent with Karadag et al.²¹ who noted no significant differences in outcomes based on patient demographics when comparing 90° and 180° conjunctival rotation autografts but emphasized the influence of pterygium characteristics on recurrence rates.

Complications varied across studies. Gupta et al.¹⁸ and Koranyi et al.¹⁹ both noted risks associated with MMC, such as scleral thinning and delayed epithelial healing, which align with the mild complications observed in our MMC group. In contrast, rotational conjunctival flap techniques in our study and those of Ozsutcu et al.¹⁷ showed fewer complications, supporting

the safety profile of this technique. These findings collectively emphasize the critical role of surgical techniques in managing primary pterygium, with rotational conjunctival flap and conjunctival autografting demonstrating superior efficacy and safety profiles compared to adjunctive MMC. While recurrence remains a challenge across all methods, our study and others highlight the importance of tailoring surgical approaches based on patient demographics, pterygium characteristics, and long-term considerations. Future research should continue to refine these techniques and explore innovative strategies to further minimize recurrence rates and enhance patient outcomes.

However, our study has certain limitations. Being a single-center study, the findings may not be generalizable to diverse populations or different clinical settings. Additionally, the follow-up period, while sufficient to capture early recurrences, may not fully account for late-onset recurrences, particularly in MMC-treated cases. Lastly, variability in surgical expertise and technique standardization across centers could also influence outcomes, underscoring the need for multicenter trials with larger sample sizes and longer follow-up durations.

CONCLUSION

Our study has concluded that rotational conjunctival flap surgery is more effective than mitomycin C in preventing recurrence of primary pterygium following surgical removal. The superior outcomes observed with the rotational conjunctival flap highlight the importance of anatomical restoration in reducing recurrence rates while maintaining a favorable safety profile. This approach proves particularly beneficial across various demographic and clinical subgroups, offering a reliable and effective surgical option for managing primary pterygium.

Acknowledgments

We deeply value the unwavering efforts of the medical team in maintaining precise records and ensuring the organized handling of patient information. Their commitment is sincerely recognized and appreciated.

Author's Contribution

The authors have played significant roles in the creation of this manuscript, as outlined below.

Dr. Akhtar Amin took the lead in designing the study, drafting the article, and gathering data from the hospital.

Dr. Arshad Iqbal was actively involved in developing the manuscript, shaping the study framework, and analyzing and interpreting the data.

REFERENCES

1. Shahraki, T., Arabi, A., & Feizi, S. (2021). Pterygium: an update on pathophysiology, clinical features, and management. *Therapeutic Advances in Ophthalmology*, 13. <https://doi.org/10.1177/25158414211020152>
2. Tandon, R., Vashist, P., Gupta, N., Gupta, V., Yadav, S., Deka, D., Singh, S., Vishwanath, K., & Murthy, G. V. (2022). The association of sun exposure, ultraviolet radiation effects and other risk factors for pterygium (the SURE RISK for pterygium study) in geographically diverse adult (≥ 40 years) rural populations of India -3rd report of the ICMR-EYE SEE study group. *PLOS ONE*, 17(7), e0270065. <https://doi.org/10.1371/journal.pone.0270065>
3. Yoon, C. H., Seol, B. R., & Choi, H. J. (2023). Effect of pterygium on corneal astigmatism, irregularity and higher-order aberrations: A comparative study with normal fellow eyes. *Scientific Reports*, 13(1). <https://doi.org/10.1038/s41598-023-34466-4>
4. Böhm, E. W., Buonfiglio, F., Voigt, A. M., Bachmann, P., Safi, T., Pfeiffer, N., & Gericke, A. (2023). Oxidative stress in the eye and its role in the pathophysiology of ocular diseases. *Redox Biology*, 68, 102967. <https://doi.org/10.1016/j.redox.2023.102967>
5. Ghiasian, L., Samavat, B., Hadi, Y., Arbab, M., & Abolfathzadeh, N. (2021). Recurrent pterygium. *Journal of Current Ophthalmology*, 33(4), 367-378. https://doi.org/10.4103/joco.joco_153_20
6. Kodavoor, S. K., Joseph, A. J., Ramamurthy, S., & Dandapani, R. (2024). Management of pterygium: our experience and a simplified treatment algorithm. *Romanian Journal of Ophthalmology*, 68(2). <https://doi.org/10.22336/rjo.2024.21>
7. Rivera-Morales, P., Barnard, L., Linderman, W., Gill, M., & Diaz, V. (2023). Surgical time and postoperative symptoms study in pterygium excision and amniotic membrane Graft using Celularity triple layer dehydrated amniotic membrane. *Clinical Ophthalmology*, 17, 1967-1974. <https://doi.org/10.2147/oph.s410452>
8. Taher, N. O., Alnabihi, A. N., Hersi, R. M., Alrajhi, R. K., Alzahrani, R. A., Batais, W. T., Mofiti, A. H., & Alghamdi, S. A. (2022). Amniotic membrane transplantation and conjunctival autograft combined with mitomycin C for the management of primary pterygium: A systematic review and meta-analysis. *Frontiers in Medicine*, 9. <https://doi.org/10.3389/fmed.2022.981663>
9. Gudimetla, J., Potti, S., Shivaprasad, S., Bhide, M., & Prabhakar, V. (2023). Pterygium surgery using inferior rotational conjunctival autograft versus conventional conjunctival autograft with sutures – A comparative study. *Indian Journal of Ophthalmology*, 71(12), 3646-3651. https://doi.org/10.4103/ijo.ijo_16_23
10. Krishna, D., Khan, M. M., Dubepuria, R., chaturvedi, G., & Cheruvu, V. P. (2023). Reconstruction of scalp and forehead defects: Options and strategies. *Cureus*. <https://doi.org/10.7759/cureus.41479>
11. Hassan, H. T. (2020). The role of Mitomycin-C (MMC) in primary pterygium surgery for prevention of recurrence. *Clinical Ophthalmologist Journal*, 1(1), 019-28.
12. Aziza, Y., Inatomi, T., Sotozono, C., & Kinoshita, S. (2020). Pterygium excision with modified bare sclera technique combined with mitomycin C. *Japanese Journal of Ophthalmology*, 65(1), 89-96. <https://doi.org/10.1007/s10384-020-00786-5>
13. Raiskup, F. (2004). Mitomycin C for pterygium: long term evaluation. *British Journal of Ophthalmology*, 88(11), 1425–1428. <https://doi.org/10.1136/bjo.2003.039891>
14. Crespo, M. A., Rapuano, C. J., & Syed, Z. A. (2023). Applications of Mitomycin C in cornea and external disease. *Turkish Journal of Ophthalmology*, 53(3), 175-182. <https://doi.org/10.4274/tjo.galenos.2023.97932>
15. Gupta, V., Sanghi, S., Rohatgi, J., & Dhaliwal, U. (2019). Outcomes of preoperative intrapterygial injection of mitomycin C for pterygium excision with and without inferior conjunctival flap. *Oman Journal of Ophthalmology*, 12(3), 171. https://doi.org/10.4103/ojo.ojo_129_2018
16. Narsani, A. K., Jatoi, S. M., Khanzada, M. A., Dabir, S. A., & Gul, S. (2008). Recurrence of pterygium with conjunctival autograft versus mitomycin C. *Pakistan Journal of Ophthalmology*, 24(01). <https://doi.org/10.36351/pjo.v24i01.733>
17. Ozsutcu, M., Ayintap, E., Akkan, J. U., Koysak, A., & Aras, C. (2014). Repeated bevacizumab injections versus mitomycin C in rotational conjunctival flap for prevention of pterygium recurrence. *Indian Journal of Ophthalmology*, 62(4), 407. <https://doi.org/10.4103/0301-4738.120220>
18. Gupta, M. L., Meena, R. K., & Bhardwaj, D. V. (2016). A clinical study of comparison of pterygium surgery with and without mitomycin-C on bare sclera technique. *International*

19. *Journal of Medical Research and Review*, 4(1), 33-37.
<https://doi.org/10.17511/ijmrr.2016.i01.005>
20. Alpay, A., Uğurbaş, S. H., & Erdoğan, B. (2009). Comparing techniques for pterygium surgery. *Clinical Ophthalmology*, 3, 69–74.
<https://doi.org/10.2147/opth.s12160130>
21. Karadag, R., Sevimli, N., Okumus, S., Ozsoy, I., Bayramlar, H., Durucu, E., Aksoy, U., & Rapuano, C. J. (2017). A comparison of two conjunctival rotation autograft techniques in primary pterygium surgery. *Arquivos Brasileiros de Oftalmologia*, 80(6).
<https://doi.org/10.5935/0004-2749.20170091>
19. Koranyi, G., Artzén, D., Seregard, S., & Kopp, E. D. (2012). Intraoperative mitomycin C versus autologous conjunctival autograft in surgery of primary pterygium with four-year follow-up. *Acta Ophthalmologica*, 90(3), 266-270.
<https://doi.org/10.1111/j.1755-3768.2010.01936.x>